

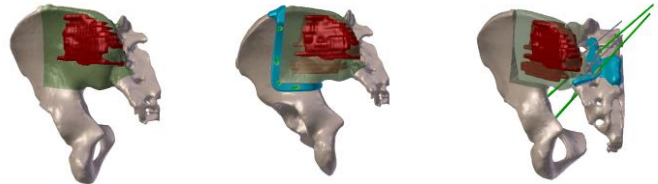
BONE TUMOR

- Surgery date: March 2016
- Surgeon: Dr. Chotel
- Hospital: Centre Pédiatrique de Lyon (France)
- Challenge: Resection of a pelvic tumor with 4 resection planes and 2 surgical guides.

COMPLEX PELVIC TUMOR RESECTION

Planning

3D-Side planned the bone tumor resection and designed the associated surgical guides.



Bone tumor resection (green)

Production

The anatomical model of the patient and the surgical guides were produced by means of high-tech 3D-Printing.



Result

The anatomical model helped the surgeon to find his marks during surgery. The surgical guides allowed to resect the bone tumor accurately, yielding excellent post-operative results.

