

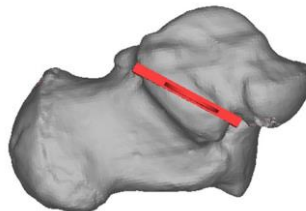
PEDIATRICS

- Surgery date: September 2016
- Surgeon: Dr. Docquier
- Hospital: Clinique Universitaire Saint-Luc (Belgium)
- Age of patient: 13 yo
- Challenge: Separating coalescent tarsal bones, restoring normal motion in the foot joints.

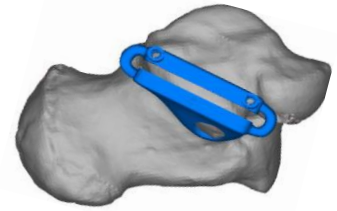
TARSAL SYNOSTOSIS OSTEOTOMY

Planning

The synostosis osteotomy of the tarsal bones was planned with our 3D design software.



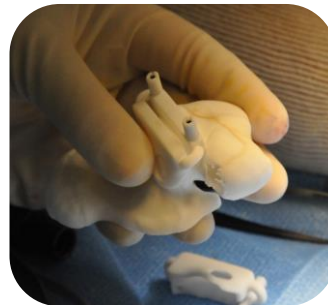Planned resection



Resection guide

Production

By means of high-tech 3D-Printing the anatomical model of the patient and the resection guide were produced.



Surgery

The anatomical model supported the surgeon during surgery. The surgical guide allowed to resect the coalescent bones accurately and until the required depth.

