

Complex Distal Femoral Tumor Resection


CHALLENGE Resection of a parosteal osteosarcoma located in the distal femur with preservation of the anterior cortex. Reconstruction using an allograft.

PRE-OPERATIVE PLANNING

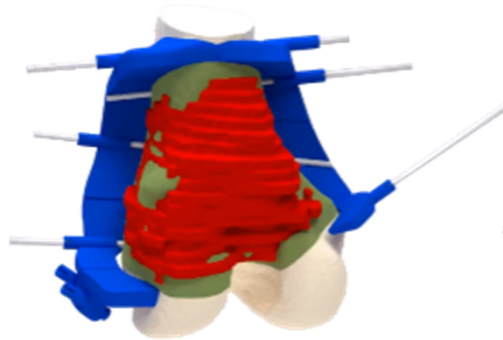
The bone tumor resection was planned based on a bilateral surgical approach, to preserve a significant portion of the medial condyle, using a second guide. Two surgical resection guides were designed, one for each side. The second guide was connected to the first one through a proximal structure and a shared K-wire to enhance their stability. 2 lateral K-wires targeted the edge of the condyle to ensure a perfect positioning during the surgery by acquiring a fluoroscopy.

The following points were taken into account:


- Safe margin : 3mm (low grade tumor)
- Preserving the continuity of the femur anterior cortex
- Avoiding contact with the lateral and medial ligament insertions



Resection planning based on tumor delineated on the MRI and matched on the CT



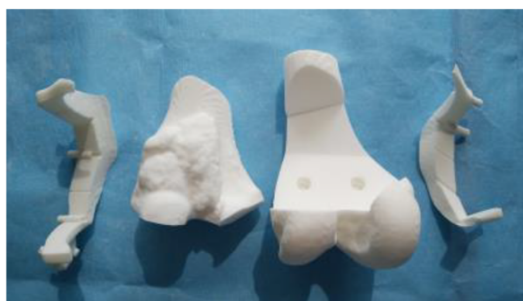Design of the surgical guides



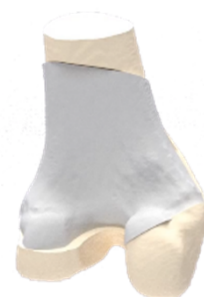A shared K-wire ensures the final stability of this guide

SURGERY

The bone models and surgical guides were sterilized at the hospital. The bone models were used in the OR to navigate the surgical approach, assess the good positioning of the guides and control the resection quality.



Surgical guide and bone model – both sterile to guide the surgery



Result of the reconstruction

The utilization of an allograft allowed the surgeon to accurately reconstruct the defect.

Note: the allograft guide is not available for sale in the USA.

